

GREAT AURICULAR NERVE TUBERCULOSIS: CASE REPORT AND REVIEW

RAMESHWAR NATH CHAURASIA¹, SHALINI JAISWAL², VIJAY NATH MISHRA³ & DEEPIKA JOSHI⁴

^{1,3,4}Department of Neurology, Institute of Medical Sciences, Banaras Hindu University Varanasi, Uttar Pradesh, India

²Department of Radiodiagnosis, Suvidha Diagnostic centre, Bhelupura, Varanasi, Uttar Pradesh, India

ABSTRACT

Tuberculosis (TB) is an infectious disease caused by *Mycobacterium tuberculosis*, a quite common health problem in many developing countries including India. Peripheral neuropathy due to tuberculosis is rare and a bit controversial. Here we report a 30 years old male clinically presenting with a tubular swelling in right lateral aspect of neck for last 10 months, which later proved to be due to tuberculous neuritis of great auricular nerve (GAN), pathologically.

KEYWORDS: Anti Tubercular Treatment, Great Auricular Nerve, Multi Drug Therapy, Tuberculous Neuropathy

ABBREVIATIONS

Tuberculosis (TB), Great Auricular Nerve (GAN), Peripheral Nervous system (PNS), Multi drug Therapy (MDT), Human Immunodeficiency Virus (HIV), Fine Needle Aspiration Cytology (FNAC)

INTRODUCTION

Involvement of the peripheral nervous system (PNS) by *Mycobacterium tuberculosis*, is controversial and rare. Many possibilities have been studied, with no definite single cause [1]. Possibilities include the toxic effects of anti tubercular drugs (especially, rifampicin, streptomycin & ethambutol), immune mediated neuropathy, leprosy, sarcoidosis, vasculitic neuropathy, compressive neuropathy, and meningitic reaction. The causative association of peripheral neuropathy with tuberculous infection is rare and till date only few cases have been reported [2, 3, 4]. We are reporting a rare case of a patient who developed tuberculosis of great auricular nerve.

CASE PRESENTATION

A 30 year old male presented to our neurology out-patient clinic with a cord like swelling localised to right lateral aspect of neck for last 10 months. Along with this he also noticed some discoloration over face and ear on same side. On examination there was a tubular, firm cord like, subcutaneous tender lump (of approx. 5cm×1.2cm) on right lateral aspect of neck along with reddish discoloration on ipsilateral aspect of cheek involving the skin over mandibular ramus, right parotid, lower concha and ear lobule i.e. along the typical distribution of anterior and posterior branches of Great Auricular Nerve (Figure 1). Sensory examination showed impaired pain and temperature sensation on corresponding area. Rest of nervous system examination was normal. Other systemic examination like respiratory and abdomen were normal. General examination including lymph node evaluation revealed no abnormality.

Patient had initially taken six months multi drug therapy (MDT) for leprosy from elsewhere without any improvement. Initially there was no patch but after few weeks of multi drug therapy, there was appearance of pigmented patches in the skin in the above mentioned distribution. Drugs included in MDT were Rifampicin, Doxycycline and Clofazimine

Investigation

Serum biochemical and hematological parameters were normal except erythrocyte sedimentation rate (ESR), which was 46 mm at the end of 1st hour by Wintrobe method. Plain X-rays of the chest and neck were normal. The patient was non-reactive for HIV I and II. On Neck ultrasonography it was reported as a linear tubular anechoic to hypoechoic slightly heterogeneous avascular cord like lesion just adjacent and overlying the right sternocleidomastoid muscle extending near the angle of jaw and to the postauricular region (approximately 6cm×1.1cm). The right internal and external jugular, retromandibular, post auricular and maxillary veins showed normal course, caliber and colour flow without any thrombus. Subsequently the final diagnosis on USG was a superficial nerve thickening which anatomically was Great Auricular nerve. No significant cervical lymph nodes were seen. Because of the clinical suspicion of a non leprotic nerve lesion of the neck, fine needle aspiration cytology study of the swelling was performed as patient did not give consent for biopsy. Smear on hematoxylin and eosinophil staining showed degenerated mixed inflammatory cells on a background of necrosis, epitheloid cells, lymphocytes and granuloma suggestive of tubercular caseating granuloma (Figure 2). No foamy macrophages (Lepra cells) were seen. Ziehl Neelsen staining for acid fast bacilli was positive and final impression given was Tuberculous neuropathy of GAN (Figure 3).

Differential Diagnosis

There are many diseases which can manifest as swelling in lateral aspect of neck, out of which important differential diagnoses are leprous neuritis, sarcoidosis, thrombosis of external jugular vein, and specific/non-specific lymphadenitis. Since patient initially did not improve after taking MDT for leprosy and FNAC was negative for lepra cells, leprous neuritis was ruled out. Sarcoidosis is characterized by presence of non-caseating granulomas, and External jugular vein thrombosis was ruled out on USG neck. Moreover USG also showed no evidence of significant lymphadenopathy.

DISCUSSIONS

Infection is the most common cause of neck swelling whether lymphadenopathy [5], or thickened GAN in developing countries. Most common cause for thickened GAN is leprosy. It is most commonly misdiagnosed as thrombosis of external jugular vein [6,7], by most of the physicians. Causal association of peripheral neuropathy with tuberculosis is highly uncommon. Exact mechanism of tubercular neuropathy is unknown but, it can be due to direct affection or pressure effect or entrapment by vertebral collapse, cold abscess or tubercular lymphadenitis [8, 9]. Further studies are required to elucidate the mechanism of neurotoxicity in tuberculosis and identify the putative mediators. Other factors which could be responsible for peripheral neuropathy in tuberculosis patients are malnutrition, meningitic radiculopathy and anti-tuberculous drugs like isoniazid and ethambutol [10-12]. It could be also due to *Mycobacterium avium-intracellulare infection* when associated with HIV [13].

Till date in literature only one case of isolated cervical nerve involvement following regional tuberculous lymphadenitis has been reported [2]. Where as in our case there is selective involvement of Great Auricular Nerve without any evidence of tuberculosis or other granulomatous infection elsewhere in body.

In our patient, the diagnosis of Tuberculous neuropathy was made on the basis of following points:

- No response to anti leprosy multi drug therapy taken by patient earlier.
- FNAC smears showing epitheloid granuloma and acid fast bacilli after stain.

- Good response to anti tubercular therapy.

TREATMENT AND FOLLOW UP

Patient was put on standard dose of Anti tubercular drugs (combination of four drugs rifampicin, isoniazid, pyrazinamide and ethambutol) along with Pyridoxine. In follow-up after 2 months, the size of lesion reduced upto 30%, and at 4 months, upto 70% along with improvement in sensation in corresponding areas and patient is still in follow-up on Anti TB drugs.

CONCLUSIONS

Tuberculosis is a chronic caseating granulomatous disease which can involve almost any body tissue and sometimes shows many unusual ways of presentation. Neuropathy in patients with tuberculosis is not always iatrogenic and the possibility of a primary effect on the nerves should be considered. Good response to anti-tubercular treatment also aids the retrospective diagnosis of tuberculosis in these cases. We should thus keep a high index of suspicion in such cases of unusual and atypical presentations of tuberculosis. Early diagnosis and timely initiation of anti-tubercular treatment can avoid complications such as neuropathy.

REFERENCES

1. Orell RW, King RH, Bowler JV, Ginsberg L. Peripheral nerve granuloma in a patient with tuberculosis. *J Neurol Neurosurg Psychiatry*. 2002; 73:769-772.
2. Warpe BM, Poflee SV, Pande NP, Shrikhande AV. Tuberculous neuritis: A rare sequel of a common disease. *Indian J Pathol Microbiol*. 2014; 57(1):69-71.
3. RN Chaurasia, A Kumar, S Jaiswal. Entrapment neuropathy secondary to tubercular abscess: Uncommon presentation of a common disease. *Ann Indian Acad Neurol*. 2013; 16(4):597-598
4. Goussard P, Gie RP, Kling S, Andronikou S, Janson JT, Roussouw GJ. Phrenic nerve palsy in children associated with confirmed intrathoracic tuberculosis: Diagnosis and clinical course. *Pediatr Pulmonol*. 2009; 44:345-350.
5. Sharma SK, Mohan A. Extra pulmonary tuberculosis. *Indian J Med Res*. 2004; 120:316-353.
6. Sharma VK, Dutta B, Khandpur S. Great auricular nerve abscess in borderline tuberculoid leprosy masquerading as jugular vein thrombosis. *J Assoc Physicians India*. 2006; 54:585-587.
7. Ramesh V, Jain R K, Avninder S. Great auricular nerve involvement in leprosy: Scope for misdiagnosis. *J Postgrad Med*. 2007; 53:253-254.
8. Poulouse SP, Sugath S, Gopalkrishnan KC. Tuberculosis affecting the median nerve. *Kerala J Orthop*. 2011; 24:43-45.
9. Naha K, Dasari MJ, Prabhu M. Tubercular neuritis: A new manifestation of an ancient disease. *Australas Med J*. 2011; 4: 674-676.
10. Peiris JB, Wikramasinghe HR, Chandrasekera MA. Tuberculous polyradiculitis. *Br Med J*. 1974; 4:107.
11. Tugwell P, James SL. Peripheral neuropathy with ethambutol. *Postgrad Med J*. 1972; 48: 667-670.

12. Erdem S, Kissl JT, Mendell JR. Toxic neuropathies: Drugs, metals, and alcohol. In: Mendell JR, Kissel JT, Cornblath DR, editors. *Diagnosis and Management of peripheral nerve disorders*. Oxford: Oxford University Press; 200. p. 297-343.
13. Wroblek MA, Rao C, Kozlowski PB, Sher JH. Muscle and nerve involvement in AIDS patient with disseminated Mycobacterium intracellulare infection. *Muscle Nerve*. 1989; 12:247-249.

APPENDICES

LEGENDS TO FIGURES

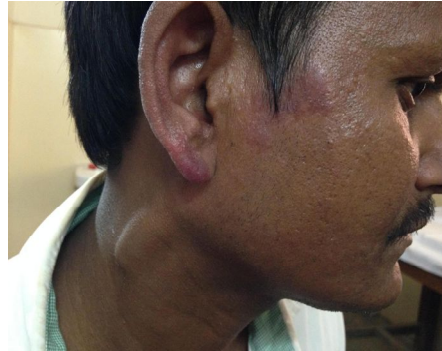

Figure 1: Image showing a Long Tubular, Firm, Subcutaneous Tender Lump of 4cm×1.2cm on Right Lateral Aspect of Neck Along with Reddish Discoloration on Upper Mandible, Parotid, Lower Concha and Ear Lobule

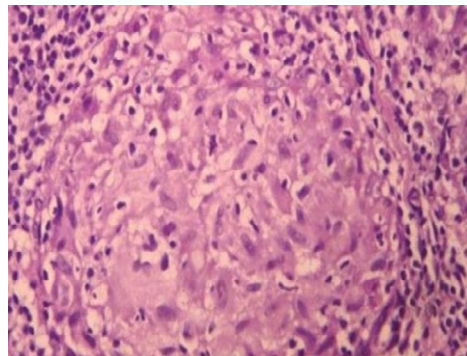


Figure 2: Hematoxylin and Eosinophilic Stain Showing degenerated Mixed Inflammatory Cells on a Background of Necrosis, Epithelioid Cells, Lymphocytes and Granuloma (Epithelioid Granuloma)

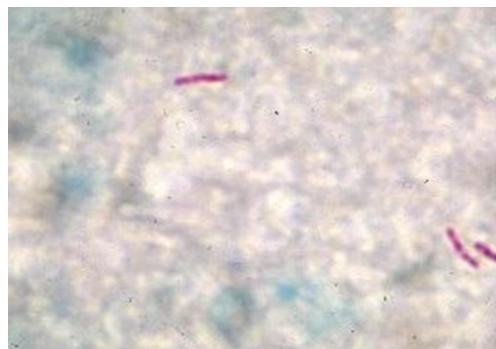


Figure 3: Ziehl-Neelsen Staining Showing Few Acid Fast Bacilli (Red Rod) with Necrosis